

HASHIMOTO THYROIDITIS IN 7-YEAR-OLD CHILDREN: A CASE REPORT

Wenny Sunardi ¹⁾, Rosalia Theodosia Dateng Beyeng ²⁾, Putu Ianta Parama Siwi³⁾

ABSTRACT

Hashimoto thyroiditis (AIT) is a common cause of hypothyroidism that can occur in childhood and adolescence (ages six to sixteen years) and often occurs in women. AIT can be determined by increases in TSH with normal thyroid hormone serum levels. The diagnosis of AIT based on clinical symptoms of hypothyroid, biochemical results, and ultrasound images. Treatment is carried out by administering levothyroxine at an initial dose of 1 – 2 µg/weight/day. This case report aims to show that AIT can show a wide range of symptoms and effects from the treatment that given to patient.

Keywords: Hashimoto thyroiditis, hypothyroidism, levothyroxine

ABSTRAK

Tiroiditis Hashimoto (AIT) merupakan penyebab umum hipotiroidisme yang dapat terjadi pada masa kanak-kanak dan remaja (usia enam hingga enam belas tahun) dan sering terjadi pada wanita. AIT dapat ditentukan melalui peningkatan TSH dengan kadar serum hormon tiroid yang normal. Diagnosis AIT didasarkan pada gejala klinis hipotiroid, hasil biokimia, dan gambar USG. Pengobatan dilakukan dengan pemberian levothyroxine dengan dosis awal 1 – 2 µg/berat badan/hari. Laporan kasus ini bertujuan untuk menunjukkan bahwa AIT dapat menunjukkan berbagai gejala dan efek dari pengobatan yang diberikan kepada pasien.

Kata kunci: Tiroiditis Hashimoto, hipotiroidisme, levotiroksin

¹⁾Faculty of Medicine, Widya Mandala Surabaya Catholic. E-mail: mdinata019@gmail.com

INTRODUCTION

Hashimoto thyroiditis (AIT) is the most common cause of hypothyroidism which can occur in childhood and adolescence and occurs more often in women than men. The prevalence of AIT in childhood peaks until mid-puberty and often occurs in areas that

contain lot of iodine. AIT is a complex multifactorial disease caused by genetic, environmental and hormonal factors, which trigger the body's immune response to the thyroid gland. Hashimoto thyroiditis can be diagnosed by the presence of anti-thyroid antibodies against peroxidase (TPOAb)

and/or anti-thyroid antibodies against thyroglobulin (TGAb), and can be confirmed using ultrasonography of the thyroid gland.^{1,5} Treatment for hypothyroidism by replacement of the thyroid hormone. Drug of choice is titrated levothyroxine sodium administered orally. It has a half-life of 7 days and can be administered daily. The initial dose of levothyroxine is 1 – 2 μ g/weight/day. Laboratory monitoring should be carried out every 2 months after adjustment in levothyroxine therapy until the appropriate dose is found and further monitoring can be carried out every 6 months.^{3,9} This case report describes a case of AIT in a 7-year-old girl with symptoms resembling AIT.

CASE REPORT

A 7-year-old girl came to the Children's clinic with complaints that her whole body felt like she always sweating, especially at night. Complaints have stayed for 11 months, since August 2022. The patient also complains that her heartbeat feels fast. Patients complain of frequent pain in the joint areas of the body, especially both knees and elbows. The initial pain was the knees joint and recently spread to the elbow area. The patient's mother complained that there was a small lump on the left side of her neck but it was visible when the child looked up or when she screamed. Apart from that, the patient's mother complained

that the child had difficulty gaining weight. Daily activities are still normal, the child's appetite and drinking habit are still normal. From the family history, it was found that the patient's grandmother also has a history of hyperthyroidism.

On physical examination, body weight was found to be 18 kg with a height of 110 cm. General examination revealed a lump in the upper left neck when the patient looked up with a diameter of approximately 4 cm. Chest examination revealed a single irregular S1S2 heart sound. Other examinations were within normal limits. During the supporting examination, a laboratory examination was carried out and it was found that the TSHS level was increased (17.01) while the FT4 level was normal (1.06).

Because the results of the examination showed that there was subcutaneous hypothyroidism and cause Hashimoto's thyroiditis, the patient was treated by administering levothyroxine 1 mcg/weight/day ~ 18 mcg/day ~ 10 mcg every 12 hours. The patient was asked to return to another physical examination after 2 weeks for further evaluation.

After 2 weeks of administering levothyroxine at a dose of 1 mcg/weight/day, the patient's mother said that complaints of sweating had begun to decrease, especially sweating at night, joint

pain also reduced, only remaining in the knees. Complaints of pounding are still but felt less compared to the first 2 weeks. From physical examination, the heartbeat already sounded regular..

DISCUSSION

Hashimoto thyroiditis (AIT) is the most common cause of hypothyroidism which can occur in childhood and adolescence and occurs more often in women than men. The prevalence of AIT in childhood peaks until mid-puberty and often occurs in areas that contain lot of iodine. AIT is a complex multifactorial disease caused by genetic, environmental and hormonal factors, which trigger the body's immune response to the thyroid gland. Hashimoto thyroiditis can be diagnosed by the presence of anti-thyroid antibodies against peroxidase (TPOAb) and/or anti-thyroid antibodies against thyroglobulin (TGAb), and can be confirmed using ultrasonography of the thyroid gland.^{1,5}

AIT develops antibodies against various thyroid antigens, the most common is anti-thyroid peroxidase (anti-TPO), many also form antithyroglobulin (anti-Tg) and TSH receptor blocking antibodies which attack thyroid tissue and ultimately lead to inadequate thyroid hormone production. Hashimoto's thyroiditis also associated with several other autoimmune diseases such as pernicious anemia, adrenal insufficiency,

and celiac disease. In United States and in areas where iodine intake is sufficient, Hashimoto's thyroiditis is the most common cause of hypothyroidism in children after 6 years of age.³ In Indonesia, the prevalence of hyperthyroidism is around 0.4% of the world population.⁴ As stated that approximately 4% - 8% of the Indonesian population suffers from hyperthyroidism.

The clinical manifestations of AIT are related to the patient's thyroid status because children with Hashimoto's can be found in a euthyroid state, mild or severe subclinical hypothyroidism, and can also occur in the form of Hashitoxicosis. In an euthyroid state, thyroid function tests are found to be within normal limits and there are no symptoms other than the discovery of a goiter. Subclinical hypothyroidism in AIT defined by elevated TSH with normal thyroid hormone serum levels, and usually classified as mild (TSH 4.5–10 mIU/l) or severe (TSH > 10 mIU/l). As seen from the patient's thyroid function test are found to be severe hypothyroidism (TSH level increased 17.01). To diagnose AIT takes time, because the most common findings based on laboratory results, namely an increase in the TSH hormone and sometimes low FT4 coupled with an increase in peroxidase antibodies (TPO).^{1,2,3}

From the patient's symptoms like always sweating especially at night, the heartbeat feels fast, frequent pain around the joints area. Based on scientific journal, patient with AIT can also have early symptoms may include constipation, fatigue, dry skin, and weight gain. More advanced symptoms may include: cold intolerance, nerve deafness, peripheral neuropathy, decreased energy, depression, dementia, muscle cramps, joint pain, hair loss, apnea, menorrhagia, and symptoms of pressure in the neck due to an enlarged goiter such as hoarseness. Patients also may have fluid accumulation in the pleural and pericardial cavities.³

Early in disease exposure, patients may show normal values because thyroid gland cell destruction may be intermittent. Some signs and symptoms can resemble hypothyroidism, such as cold, dry, yellowish and thickened skin caused by accumulation of hyaluronic acid and dry skin, especially on the extensors, soles and heels due to atrophy of the sweat glands. Coarse hair and hair loss, a hoarse voice caused by edema in the vocal cords, and the respiratory system affected due to bradypnea and hypoxia caused by obstruction of the upper airways due to an enlargement of the thyroid gland. Rough facial features, facial edema, bradycardia, and decreased contractility and reflexes

cause cramps in the skeletal muscles. In the systemic problems, a decrease in peristalsis can be found which can cause constipation and even ileus. In addition, gallbladder hypotonia can occur which can lead formation of gallstones. Effects on the central nervous system that can occur are fatigue, depression, memory loss, and inability to concentrate.^{7,3}

The diagnosis of AIT based on clinical symptoms of hypothyroidism and the presence of TPOAbs, although seronegative results may be seen in 5%-10% of cases. Biochemical features show increased thyroid-stimulating hormone (TSH) in response to low free T4. Low total or free T4 levels in the presence of high TSH levels confirm the diagnosis of primary hypothyroidism. Ultrasound imaging of the thyroid gland can also help for differential diagnosis, especially in patients with TPOAbs-negative. ^{1,3}, As seen from the patient's ultrasound result, there are lymphadenopathy in submandibular and cervical bilateral. Based on researches, Thyroid ultrasound assesses thyroid size, echo texture, and whether thyroid nodules are present. Ultrasound features of AIT include decreased echogenicity, heterogeneity, hypervascularity, and the presence of small cysts. Serum anti-TPOAbs are present in approximately 95% of patients, with anti-

TgAb positivity in 60%–80%. Anemia is seen in 30 - 40%. There can also be a decrease in glomerular filtration rate (GFR), renal plasma flow, and renal free water clearance resulting in hyponatremia. Creatine kinase frequently increase. Prolactin levels may increase. Increased levels of total cholesterol, LDL, and triglycerides may occur.^{3,8}

Treatment for hypothyroidism is thyroid hormone replacement. The drug of choice is titrated levothyroxine sodium administered orally. It has a half-life of 7 days and can be administered daily. The initial dose of levothyroxine is 1–2 $\mu\text{g}/\text{kg}/\text{day}$. It should not be administered

with iron or calcium supplements, aluminum hydroxide, and proton pump inhibitors to avoid suboptimal absorption. Best taken in the morning with empty stomach for optimal absorption. The standard dose around 1.6 - 1.8 mcg/kg per day. Laboratory monitoring should be carried out every 2 months after a change in levothyroxine therapy until the appropriate dose is found and further monitoring can be carried out every 6 months.^{3,9} In this patient, it was started with a low dose, namely given with an initial dose of 1 $\text{mcg}/\text{kg}/\text{day}$, which was then increased the dose during the second control for 2 $\text{mcg}/\text{kg}/\text{day}$.

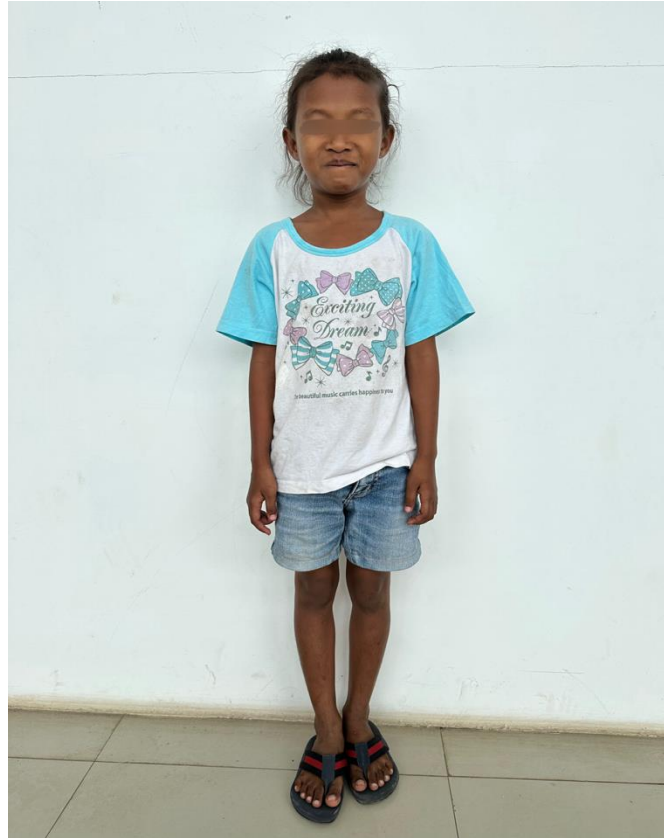

Figure 1. Stature of Patients with Hashimoto's Thyroiditis

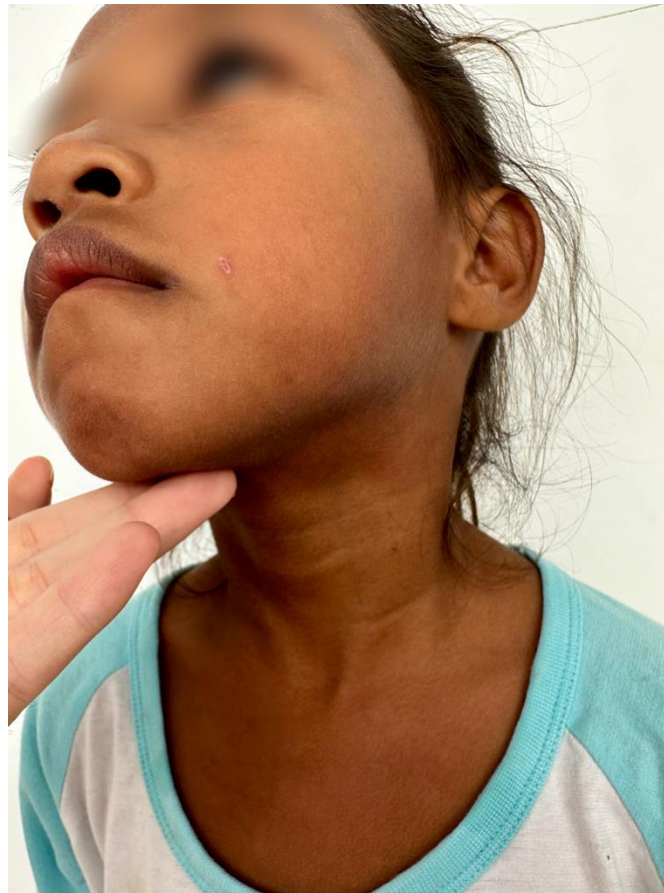

Figure 2. Clinical Photograph of a Patient with Hashimoto Thyroiditis

URAIAN HASIL PEMERIKSAAN
Klinis : Tiroiditis Hashimoto
TS. Yth. USG Thyroid :
<ul style="list-style-type: none">- Thyroid kanan : ukuran normal, intensitas echoparenchyme normoechoic, tak tampak lesi hipo/iso/hiperechoic, pada CDUS tak tampak peningkatan vascularisasi- Thyroid kiri : ukuran normal, intensitas echoparenchyme normoechoic, tak tampak lesi hipo/iso/hiperechoic, pada CDUS tak tampak peningkatan vascularisasi- Isthmus : ukuran normal, intensitas echoparenchyme normoechoic, tak tampak lesi hipo/iso/hiperechoic, pada CDUS tak tampak peningkatan vascularisasi- Tampak pembesaran kelenjar getah bening submandibular dan cervical kanan kiri
Kesimpulan :
<ul style="list-style-type: none">- Saat ini Thyroid kanan kiri tak tampak kelainan- Lymphadenopati submandibular dan cervical bilateral

Figure 3. Thyroid Gland Ultrasound Examination Results

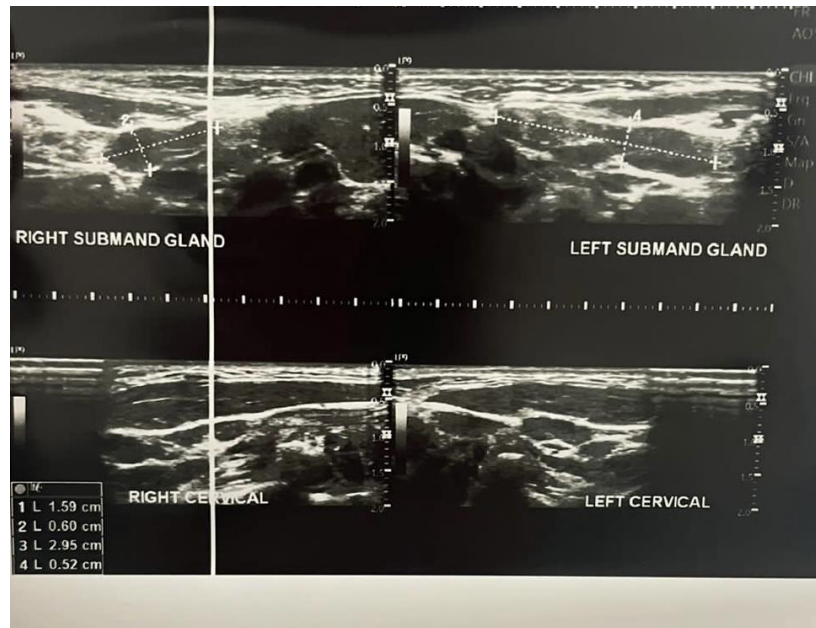


Figure 4. Results from Ultrasound Results of the Thyroid Gland

REFERENCES

1. Vukovic R, Zeljkovic A, Bufan B, Spasojevic-Kalimanovska V, Milenkovic T, Vekic J. Hashimoto thyroiditis and Dyslipidemia in childhood: A Review [Internet]. U.S. National Library of Medicine; 2019. Available from: <https://www.ncbi.nlm.nih.gov/pmc/articles/PMC6914680/>
2. De Luca F, Santucci S, Corica D, Pitrolo E, Romeo M, Aversa T. Hashimoto's thyroiditis in childhood: Presentation modes and evolution over time [Internet]. U.S. National Library of Medicine; 2013. Available from: <https://www.ncbi.nlm.nih.gov/pmc/articles/PMC3567976/>
3. Mincer DL, Jialal I [Internet]. StatPearls [Internet]; 2022. Available from: <https://www.ncbi.nlm.nih.gov/books/NBK459262/>
4. Abdullah, S.S., Lorensia, A. and SuyantoMedia Kesehatan Masyarakat Indonesia (2020) Media Kesehatan Masyarakat Indonesia - repository Universitas hasanuddin, Media Kesehatan Masyarakat Indonesia. Available at: <http://repository.unhas.ac.id/5061/3/5.%2010990.pdf>
5. Tang S, Yang M, Zhang D, Tong Y-J, Xin Y. Clinical characteristics and follow-up of 19 children with Hashimoto's thyroiditis aged below 3 years: A single-center retrospective analysis [Internet]. U.S. National Library of Medicine; 2021. Available from:

- <https://www.ncbi.nlm.nih.gov/pmc/articles/PMC8446657/>
6. Penta L, Cofini M, Lanciotti L, Leonardi A, Principi N, Esposito S. Hashimoto's disease and thyroid cancer in children: Are they associated? [Internet]. U.S. National Library of Medicine; 2018. Available from: <https://www.ncbi.nlm.nih.gov/pmc/articles/PMC6189282/>
 7. Crisafulli G, Gallizzi R, Aversa T, Salzano G, Valenzise M, Wasniewska M, et al. Thyroid function test evolution in children with Hashimoto's thyroiditis is closely conditioned by the biochemical picture at diagnosis [Internet]. U.S. National Library of Medicine; 2018. Available from: <https://www.ncbi.nlm.nih.gov/pmc/articles/PMC5804084/>
 8. Klubo-Gwiedzinska J, Wartofsky L. Hashimoto thyroiditis: An evidence-based guide to etiology, diagnosis and treatment [Internet]. U.S. National Library of Medicine; 2022. Available from: <https://www.ncbi.nlm.nih.gov/pmc/articles/PMC9478900/>
 10. Yati NP, Utari A, Tridjaja B. Panduan Praktik Klinis Ikatan Dokter Anak Indonesia: Diagnosis dan Tata Laksana Tiroiditis Hashimoto. Vol. 1. Ikatan Dokter Anak Indonesia; 2017.